Clinical and Prognostic Significance of Brain SPECT Changes in the Default Mode Network Areas

Dan G. Pavel MD[1]; Steven R. Best MD[2]

[1]PathFinder Brain SPECT, [2]The Neuroscience Center, Deerfield, IL, 60015
Email: danpavel@pathfinder.md

Introduction

Among the clinical advantages provided by resting Brain SPECT is the evaluation of the functional status in the whole gray matter volume via detection of both areas of underperfusion (hypofunctioning) and of hyperperfusion (hyperfunctioning). A possible improvement of the image interpretation is sought, based on the importance of Resting State Networks and specifically of the Default Mode Network (DMN) in brain physiology/pathphysiology.

Brain SPECT is able to easily identify the two core medial component areas of DMN : 1. the anterior cingulate & adjacent mesial orbito-frontalareas and 2. the posterior cingulate & precuneus areas. Consequently it should become feasible to provide additional interpretation of SPECT in light of abnormalities in these areas.

Methods

In this pilot study we selected cases where it was possible to identify marked hypo or hyperperfusions in one or both components of DMN and correlate them with clinical history and outcome after some extended periods of followup.

The brain SPECT was done with a Prism 3000 XP triple head gamma camera with ultra-high resolution fan-beam collimators following i.v. injection of 99mTc_HMPAO . Processing based on reconstruction, filtering, reorientation and attenuation correction, leading to the orthogonal cuts supplemented by a fourth axial display obtained along the temporal axis. The display uses a discrete color code of 21 shades (1) and multiple thresholded volume displays. In addition the same color code was used with the automatic "Neurostat" algorithm (2) which displays 8 surface views, after normalization to the Talairach space.

Rationale for Evaluating the Functional Status of the DMN During Resting State

It is now well understood that in the brain, **at rest,** there is **ongoing activity** called **Intrinsic activity (IA)** organized in **Resting State Networks (RSN)** via **specific connectivity** between various areas. Historically the first & strongest connection found at rest was between the anterior cingulate (**AC**) and its surrounding areas, interconnected to the posterior cingulate (**PC**) and its adjacent precuneus area. This was called the Default Mode Network (**DMN**). It is also known that this **DMN** is decreasing/suspending its activity **during goal directed behaviors**, e.g. it is **anti-correlated** with **conscious** activity, meaning that the activity in the **DMN** areas is attenuated when resources are temporarily reallocated during such goal directed behaviors. Besides the DMN other areas of the brain are now known to have their own resting Intrinsic Connectivity, organized in additional resting state networks. Furthermore it is known that the **Intrinsic activity** is critical to brain function and consumes approximately 80-90% of the brain's energy budget. Among the possible functions of **IA/RSN** is the facilitation of response to stimuli.

Why Brain SPECT?

The technique seems particularly well suited for such an evaluation. Indeed it is an easy to perform, non-invasive procedure done in a resting state most of the time. It is based on the tagging of gray matter areas , proportional to their blood flow. A final distribution is obtained after just 3-4 min post injection, with no significant change up to 2-3 hours. This in turn enables the visualization of the whole gray matter volume via a 3D mapping of perfusion levels.

Consequently Brain SPECT done at REST, identifies the Functional Steady State status of the whole gray matter volume, at a given time in the evolution of a Neuropsychiatric disorder. Its main clinical indication in Neuropsychiatry is the comorbidity resulting from long term system perturbations generated by Neuropsychiatric disorders.

What it does is enable the detection of areas of relative underperfusion but, as importantly of areas of relative hyperperfusion and thus resulting in the visualization of patterns and of a feature inventory. These in turn are then used for a better understanding of the substrate of the clinical presentation and ultimately contribute to establishing the treatment strategy as well as help with prognosis and followup.

Hypothesis: an even better understanding and better prognostic information could be available if we can also look at brain SPECT from the perspective of Resting State Networks.

Demo Display

Out of the 4 pages obtained during a routine Brain SPECT, only key parts of the result are displayed in this 2 line format for demo purpose .

While brain SPECT is a functional study it is important to realize that key anatomical structures can be easily delineated.

For example in this 16 old male, among other findings it is of interest that the anterior cingulate (#3) as well as the posterior cingulate (#4) and precuneus are hyperperfused e.g. hyperfunctioning

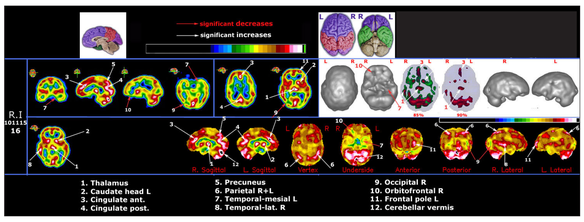

Simple Examples With Major Consequences

Extreme examples of posterior cingulate / precuneus area abnormalities as identified by Brain SPECT in 2 very different Neuropsychiatric conditions :

Example A: limbic seizures & comorbidities

Example B: Alzheimer's

- The Posterior CingulateCortex (PCC) & Precuneus are densely interconnected structures which are part of the Default Mode Network .
- Normally the activity of the DMN is suspended during goal-directed behaviors.
- What happens if these structures become functionally abnormal as demonstrated by SPECT? It leads to major system perturbations.

Case #1 Representative for DMN marked hyperfunction in BOTH its ant & post component (a & p)

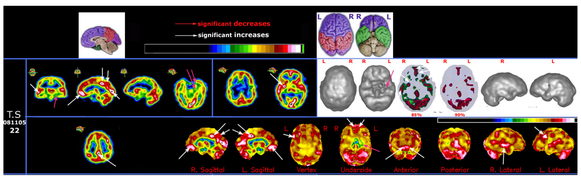

Hx: 22 y.o. m. Very difficult case. Anxiety, OCD, ETOH & drug use (mostly stimulants), impulse control difficulties including sex drive, smoker. Could not complete college.

Brain SPECT result: Multiple areas of hyperperfusion: extreme in the post cingulate (p), moderate in the precuneus; marked / extensive in rostral anterior Cingulate (a) and its adjacent structures; marked / extreme in the R putamen and multiple marked & moderate localized areas in both hemispheric surfaces.

Underperfusion: In mesial aspect of L temporal lobe.

Working Dx.: Considered to be at interface of manic depression & epilepsy (limbic type).

Followup: Required years of Rx with AED-s, antipsychotics & supplements; frequent followups, numerous Rx dose adjustments, family support, rTMS and ultimately combination therapy with TMS/Ketamine infusion.

Long term f-up: is finally doing better after 2y, has finished college and is working as a professional.

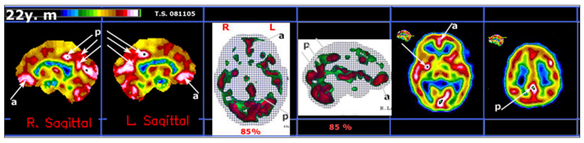

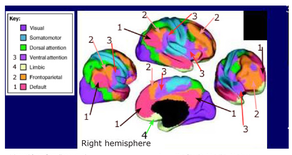

Adapted from Castellanos et al., Trends in Cognitive Sciences, 2012, vol 16, No 1.

1 = Default Mode Netw
2 = Fronto-parietal Netw
3 = Ventral attention Netw
4 = Limbic Netw

The very difficult 22 y.o patient; why?
Possible intrinsic networks integration answer

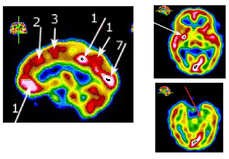

Network abnormalities: the whole DMN is extremely hyperactive (1), parts of the Frontoparietal (2) and Ventral Attention (3) networks are also increased and in additionthe Visual (7) network extremely hyperactive as well.

Hypothesis: such hyperactivity precludes the normal anti-correlation betweenseveral of the intrinsic activity networksand conscious activity. This in fact may result in an inadequate facilitation of response to stimuli and ultimately produce system perturbations leading to comorbid mental disorders.

(1) Pavel D, et al. Viewing the functional consequences of traumatic brain injury by using brain SPECT, Brain and Cognition 60 (2006) 211-213

(2) Minoshima S, et al.. Anatomical standardization: linear scaling and nonlinear warping of functional brain images. J Nucl Med. 1994;35:1528-37

Presented at the:
45th annual meeting of the
Society for Neuroscience
Oct 17-21, 2015, Chicago, IL

Case #2 Complex case of youngster with hyperfunction in the anterior & posterior aspect of the DMN

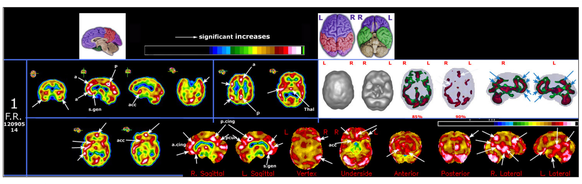

Hx: 14 y.o female. Persistent anxiety (about having to vomit!). Attention & focusing difficulties. Scared when alone. Learning problems (reading or listening and significant delay in assimilating what she reads or hears – extending to leisure time activities like the movie theater). In spite of her IEP she is very difficult to educate. Epilepsy workup.

Rx at presentation: none

EEG = Normal

Brain SPECT result. Hyperperfusions: extreme in the post cingulate, moderate in adjacent precuneus; marked in whole anterior cingulate, extending also to the subgenual area. Multiple, marked localized areas in R hemisphere and to a lesser extent on the L; orbito-frontal bilaterally; R Insula-post; frontal poles, inferior aspect of temporal apices and central aspect of thalamus. Underperfusions: none significant.

Working Dx: Dysregulated affect, mood swings. Inefficient cognition. Childhood onset bipolar disorder. Possible limbic seizures.

Rx. Post SPECT: Lamictal and subsequently added Ritalin

Followup: slow but steady progress at 2½ y. Is now fully educable. Her capabilities in the social, interpersonal, and athletic realms have improved. Still a bit brittle but Rx was life transforming for her & family.

She is now age appropriate in all ways.

Obs: the simultaneous dysfunction of both anterior and posterior components of the DMN can lead in younger patients to what can be called inefficient cognition in a context of multiple other comorbidities.

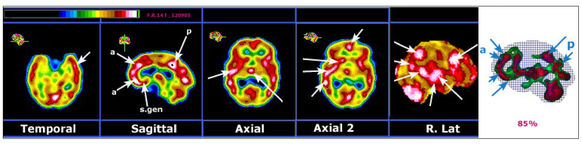

Case #3 Representative for DMN marked hyperfunction in its ANTERIOR component (a)

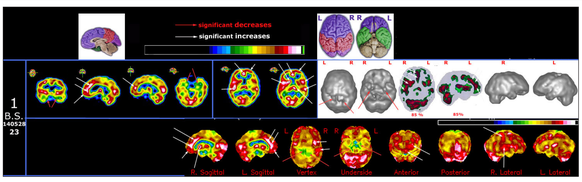

Hx: 23 y.o male. For the previous 3 years: Anxiety, affective dysregulation (cries easily), a sense of poor processing along with hyperfocusing problems (preoccupied with negative notions). Compulsive behavior, troubles including compulsive video-gamer, and mild neurotoxic exposure (THC & EtOH). Alienated from parents. Depression. Procrastinator. Headaches. Dismissed from numerous colleges. No job & no apparent motivation to act on his own behalf. Sleep complaints. Institutionalized for several months. Glib.

Brain SPECT result. Hyperperfusions: extensive and marked in the whole anterior cingulate (a) and adjoining areas. In addition extreme and/or marked in multiple subcortical areas and hemispheric surface. **Underperfusions**: in the mesial aspect of both temporals.

EEG: Normal

Working Dx: Regulatory disorder of childhood, extended into adulthood. Psychopathic trend.

Rx plan: starting on lamotrigine supposedly to be followed by (r)TMS & subsequent Neurofeedback.

Follow-up: among other things due to inadequate family environment did not follow the prescribed treatment strategy and ultimately did poorly.

Obs: the extensive anterior cingulate hyperactivity interferes with the normal functional dynamic of the anterior component of the DMN and leads to system perturbations.

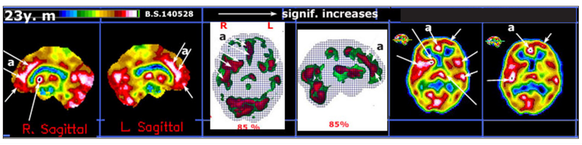

Case #4 Representative for DMN marked hyperfunction in its POSTERIOR component (p)

Hx: 45 y.o. male. Lifelong Compulsive Behavior Disorder for sex /affairs, food, internet porn, shopping. Attention & focusing problems. "Ultra-aware of things". Recent neurotoxic exposure (THC, ETOH). Hx of multiple closed head injuries in past.

Brain SPECT result: note extensive & marked posterior cingulate/precuneus **hyperpefusion** in addition to a few subcortical areas of moderate hyperperfusion. **Underperfusions** in orbito-frontal and mesial temporals areas.

Working Dx: ADD, possible limbic type seizures, perhaps post concussion syndrome.

Recommendations: addiction & marital counseling, and to complete the workup (EEG) followed by guided treatment.

Obs: The extensive posterior cingulate/precuneus hyperactivity interferes with the functional dynamic of the posterior component of the DMN and can lead to significant system perturbations.

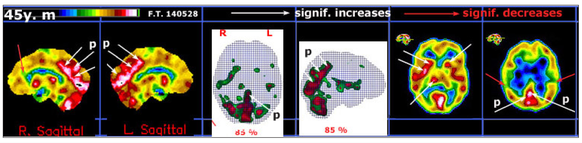

Case #5 DMN combined dysfunction. Low level in anterior component; high level in posterior component

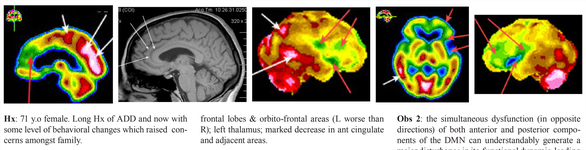

Hx: 71 y.o female. Long Hx of ADD and now with some level of behavioral changes which raised concerns amongst family.

MRI: moderate perisylvian volume loss (L>R); old lacunar infarctions in L thalamus ; possible subclinical ischemic changes in periventricular white matter.

Neuropsychological evaluation: Alzheimer's can be considered

Brain SPECT result. Hyperperfusions: marked & extensive in post cingulate/precuneus and in R supramarginal gyrus area. Underperfusions: bilateral frontal lobes & orbito-frontal areas (L worse than R); left thalamus; marked decrease in ant cingulate and adjacent areas.

Working Dx: variant of FTLD (fronto-temporal lobar degeneration). The marked increase in the post cingulate /precuneus indicates that Alzheimer's is ruled out.

Rx: repeat PSE -s (PeriSpinal injections of Ethanercept).

Obs 1: Striking contrast between the DMN components : marked decrease anteriorly vs marked increase posteriorly.

Obs 2: the simultaneous dysfunction (in opposite directions) of both anterior and posterior components of the DMN can understandably generate a major disturbance in its functional dynamic leading to system perturbations manifested in the patient's behavior .

Obs 3: Note total discrepancy between the major functional abnormality of the ant cingulate seen on SPECT and its normal appearance on MRI . The latter was confirmed independently by 2 academic Radiologists.

Results & Discussion

Results: 16 patients, ages 17-69 who had a follow-up of up to 18 mo or more. 6 had DMN underperfusions (4 in the posterior and 2 in the anterior component area) and 10 had DMN hyperperfusions (3 in both components, 4 in the posterior and 3 in the anterior component).

Underperfusions: The 4 patients with posterior DMN underperfusions were ultimately confirmed as Alzheimer's or mixed dementia. The 2 with anterior DMN underperfusion were in patients with significant comorbidity, one of them confirmed as early fronto-temporal lobar degeneration.

Hyperperfusions: The 3 patients with hyperperfusion in both components of DMN required prolonged treatment including medication, rTMS (repetitive Transcranial Magnetic Stimulation) and/or ketamine perfusion without or with augmentation with TMS). One 22 y.o. patient required intensive treatment over 2½ year involving all these protocols before transitioning from unemployable to a fully employed person with further professional goals. The remaining 8 patients with only partial DMN hyperactivity, required prolonged treatment but overall were easier to treat.

Discussion: We interpret these results in light of the known functional anti-correlation normally exhibited by the Default Mode Network (DMN) in the presence of conscious activity. Consequently the more extensive the abnormality seen on Brain SPECT in DMN areas, the more likely it is to produce a severe interference with the expected functional anti-correlation during goal directed behaviors (conscious activity). This in turn can result in prolonged brain system perturbations leading to the dysfunctions seen in comorbid mental disorders. It is important to emphasize that because of comorbidity present in all these cases, the SPECT abnormalities seen in the DMN areas were not isolated but part of a number of additional functional abnormalities detected. Consequently, a larger number of patients need to be analyzed to better determine when DMN abnormalities carry more diagnostic and/or prognostic weight.

Conclusions

- Brain SPECT functional imaging at rest, when properly implemented is a noninvasive, easily accessible method which maps the blood flow distribution in the whole gray matter volume and indirectly describes its steady state status in Neuropsychiatric disorders.
- As such it has proven itself well-suited for detecting functional abnormalities in the two main Default Mode Network components: anterior & posterior.
- The location type, extent and amount of abnormality detected in the DMN areas can suggest the level of dysfunction present in each case, lead to better clinical understanding and also provide additional prognostic information.
- If SPECT detects a major hyper or underperfusion in one or in both main DMN components it can be postulated that one of the ways in which a system perturbation is produced is via interference with the normal anti-correlation which should ordinarily occur within that region, during goal-directed behaviors.
- Additional work is needed to integrate the brain SPECT information thus obtained, in a more precise clinical context, given the extent of comorbidities present in so many Neuropsychiatric disorders.